

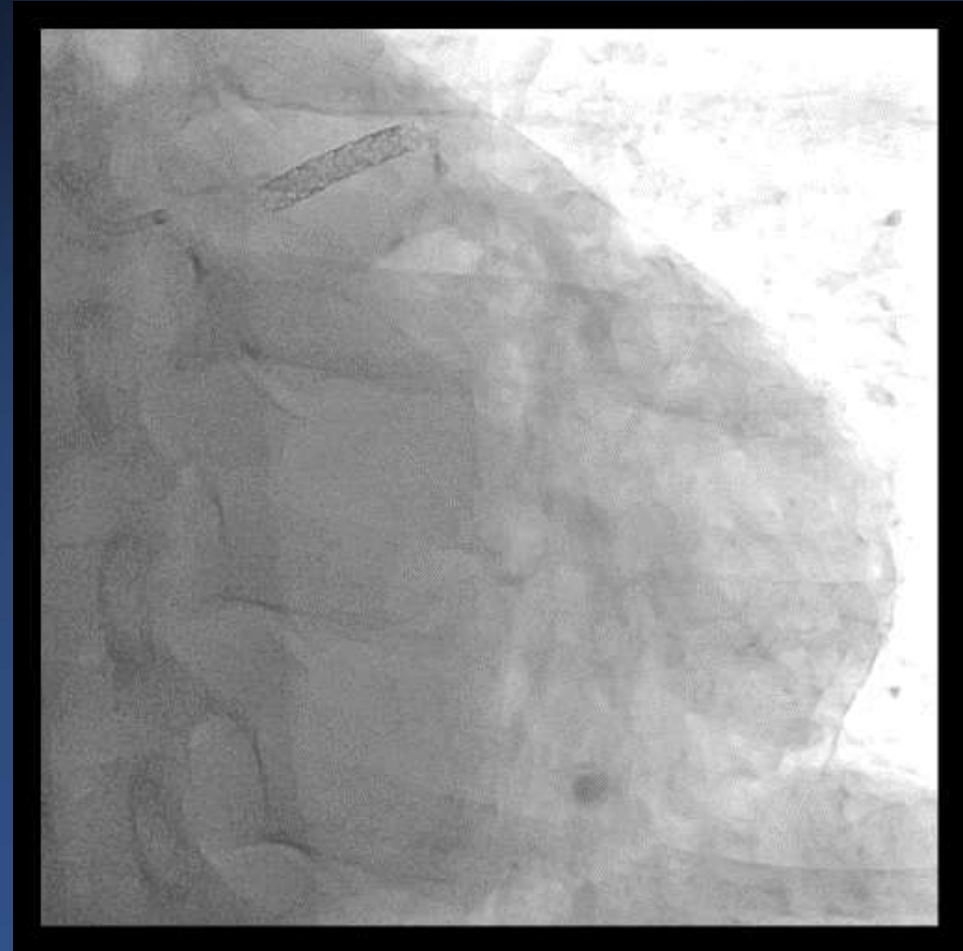
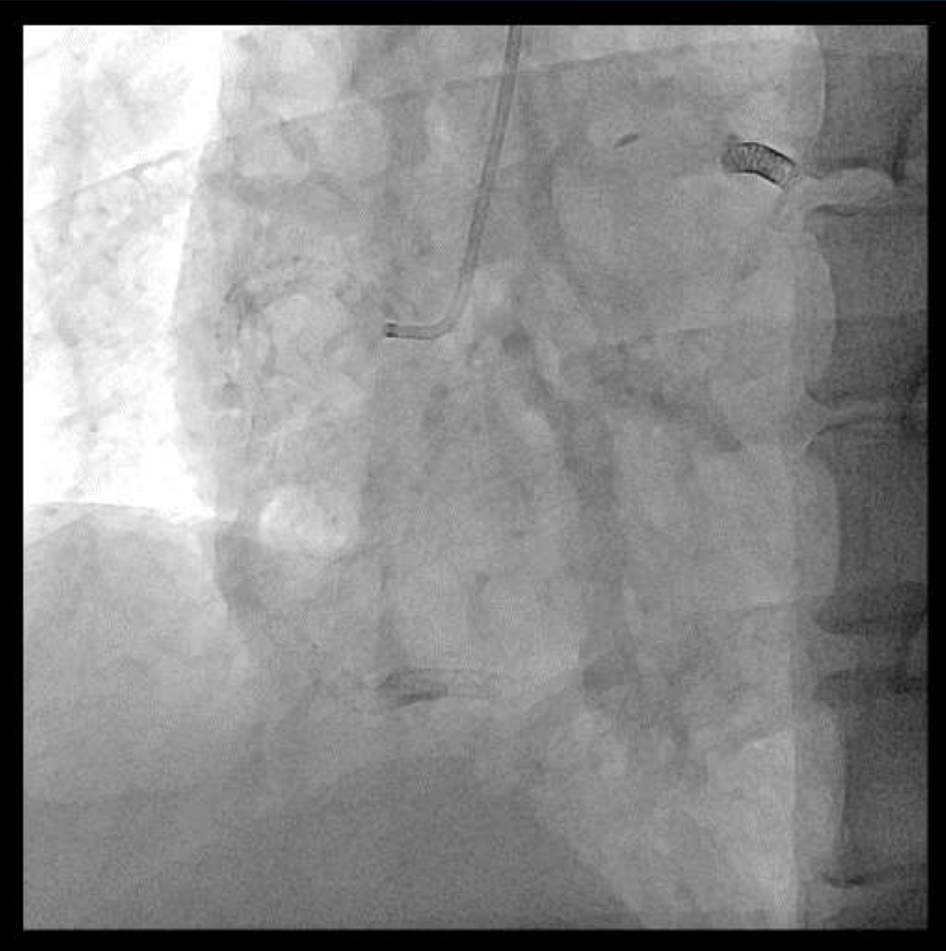Complex PCI for heavily calcified lesion

Hanbit Park, MD
Asan Medical Center

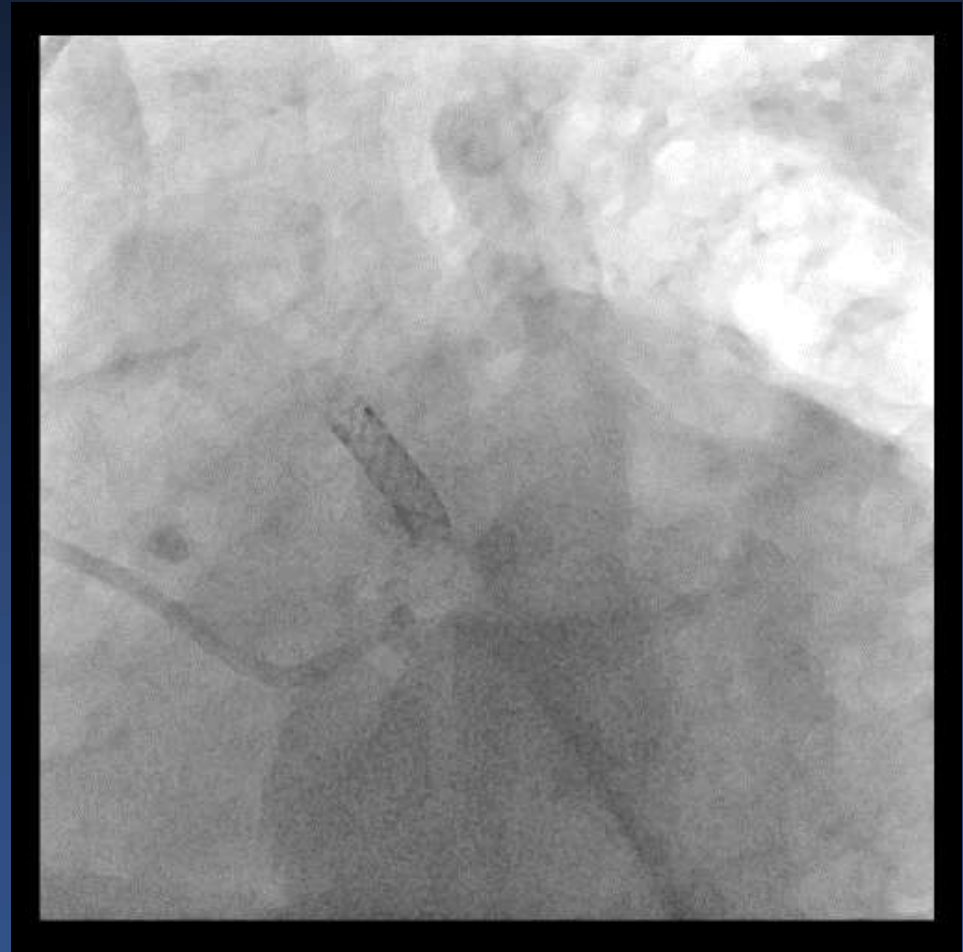
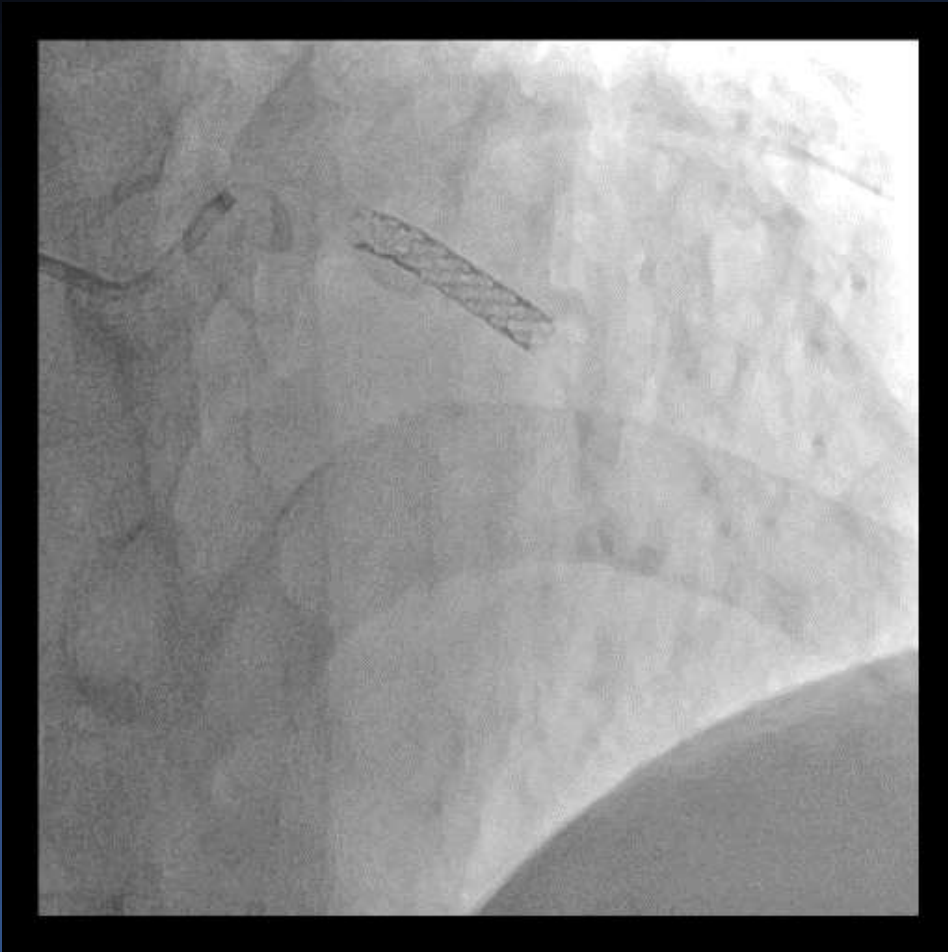
Brief case summary

- Chief complaint: resting chest discomfort(Onset: 6 HA)
- Present illness:
- A 68 years old male patient was hospitalized for resting chest pain started 6 hours ago. He received proximal LAD and OM branch stenting 17 years ago in other hospital and proximal to mid RCA and distal RCA stenting 2 years ago in our hospital. His coronary risk factors are hypertension, diabetes, hyperlipidemia and current smoker. ECG and cardiac enzyme were unremarkable.

Coronary angiography




Coronary angiography



PCI strategy

- Proximal RCA ISR
- Proximal LAD ISR
heavily calcified
 - 1) Compliant ball
 - 2) Non-compliant
 - 3) Scoring balloo
 - 4) Rotational ath




n
e stenosis with

Compliant balloon

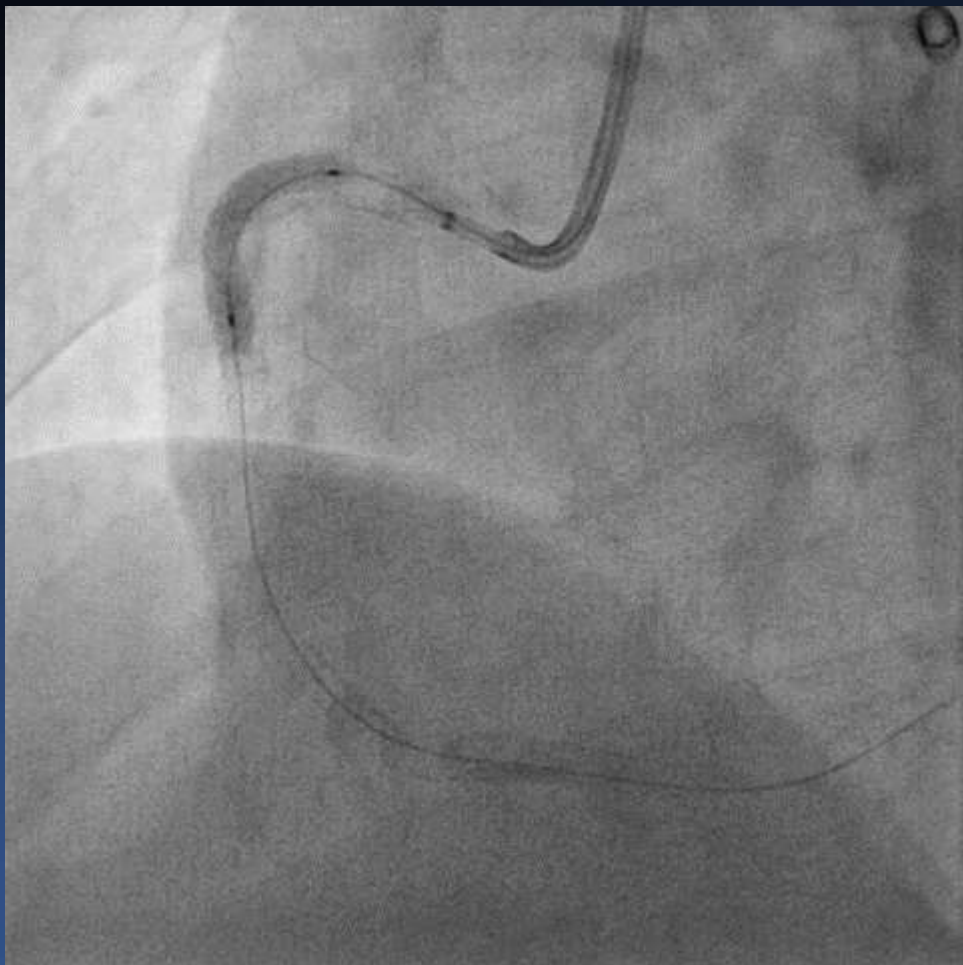
Non-compliant balloon

Scoring balloon

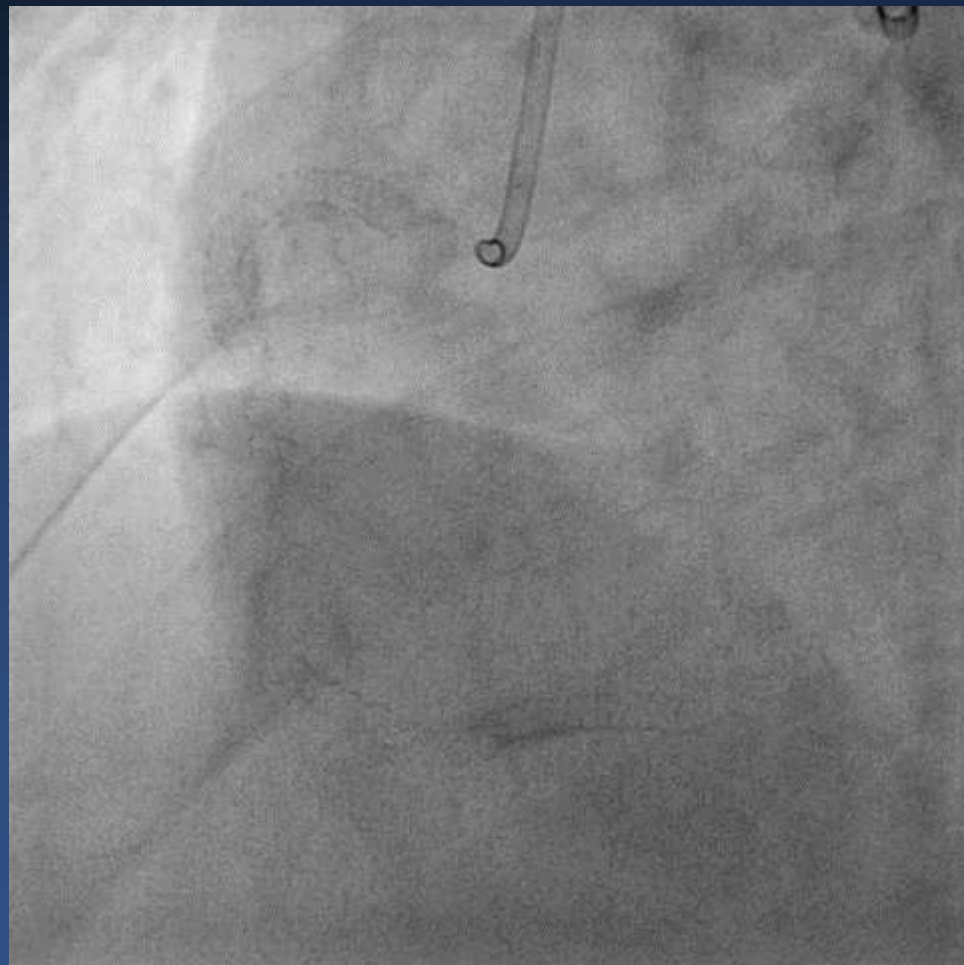
Rotablator



Proximal RCA ISR lesion

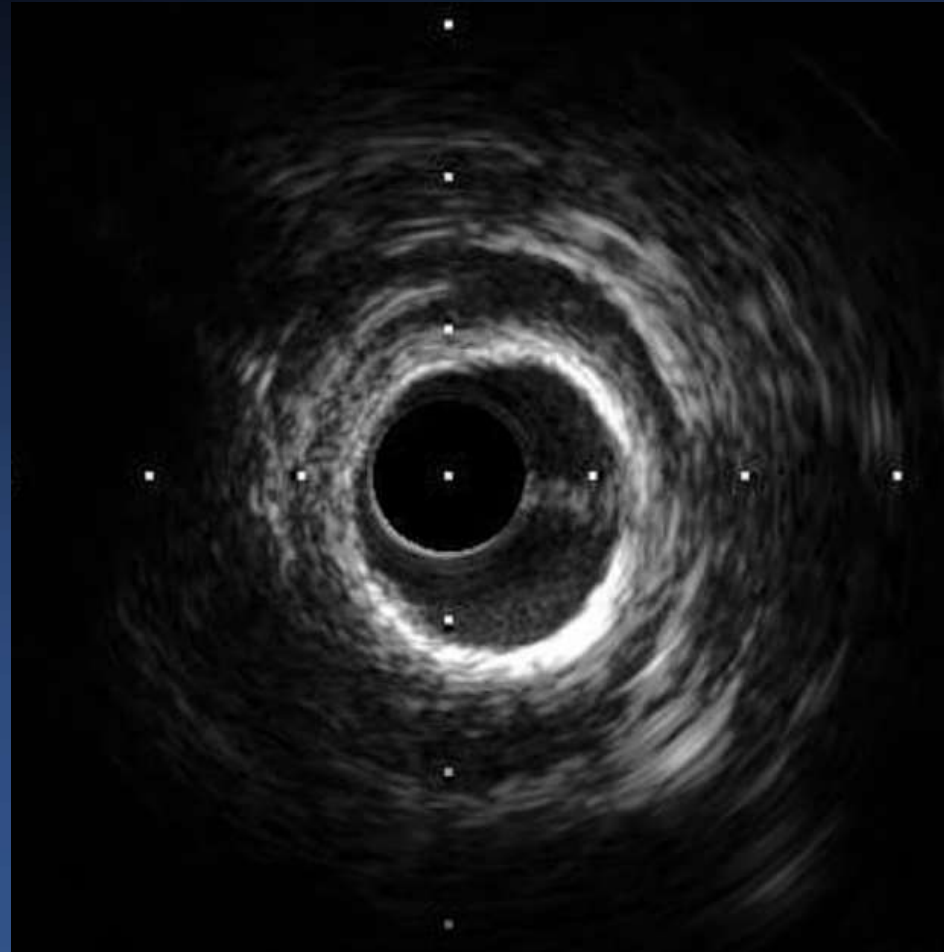


Raiden 3 4.0(20)



Pantera Lux 3.5(20) x 2

LAD lesion; baseline IVUS

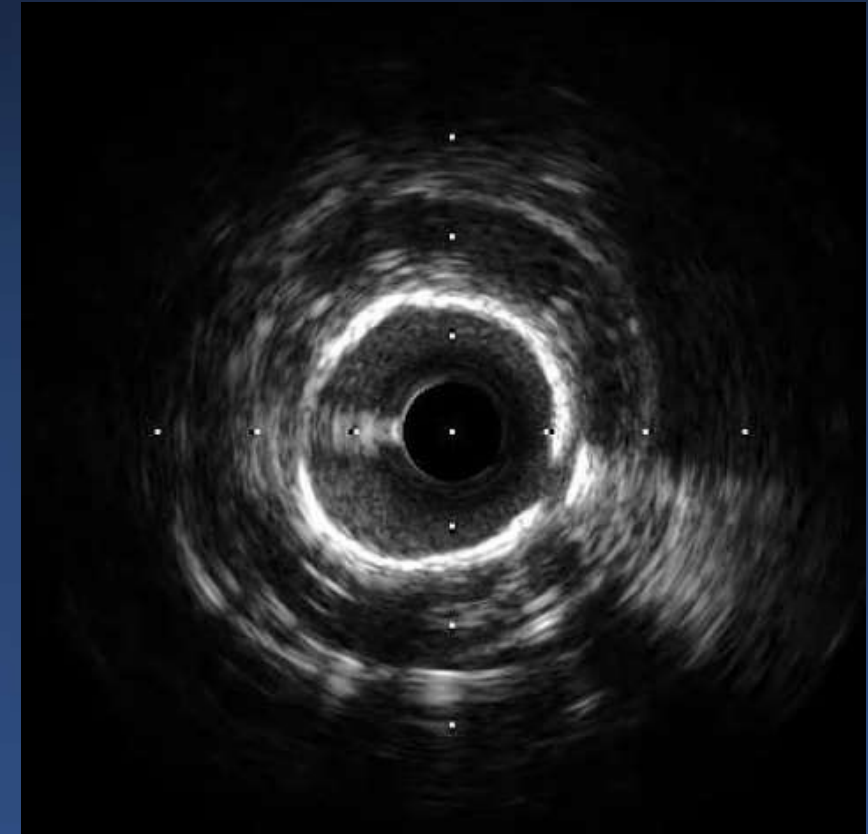
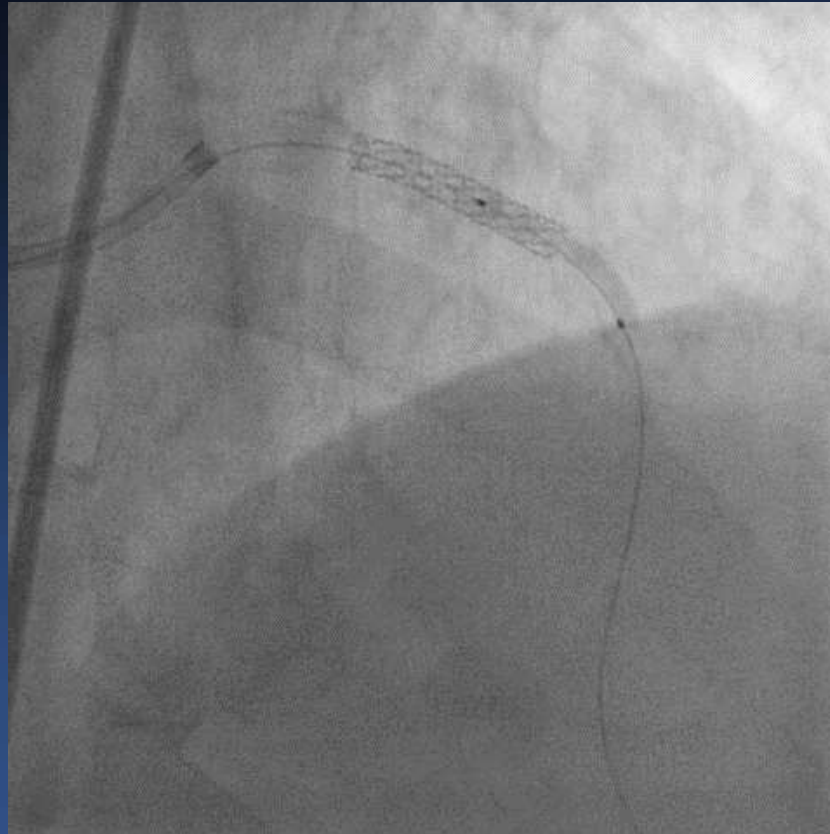


NC balloon and Scoring balloon

Euphora 2.0(20)

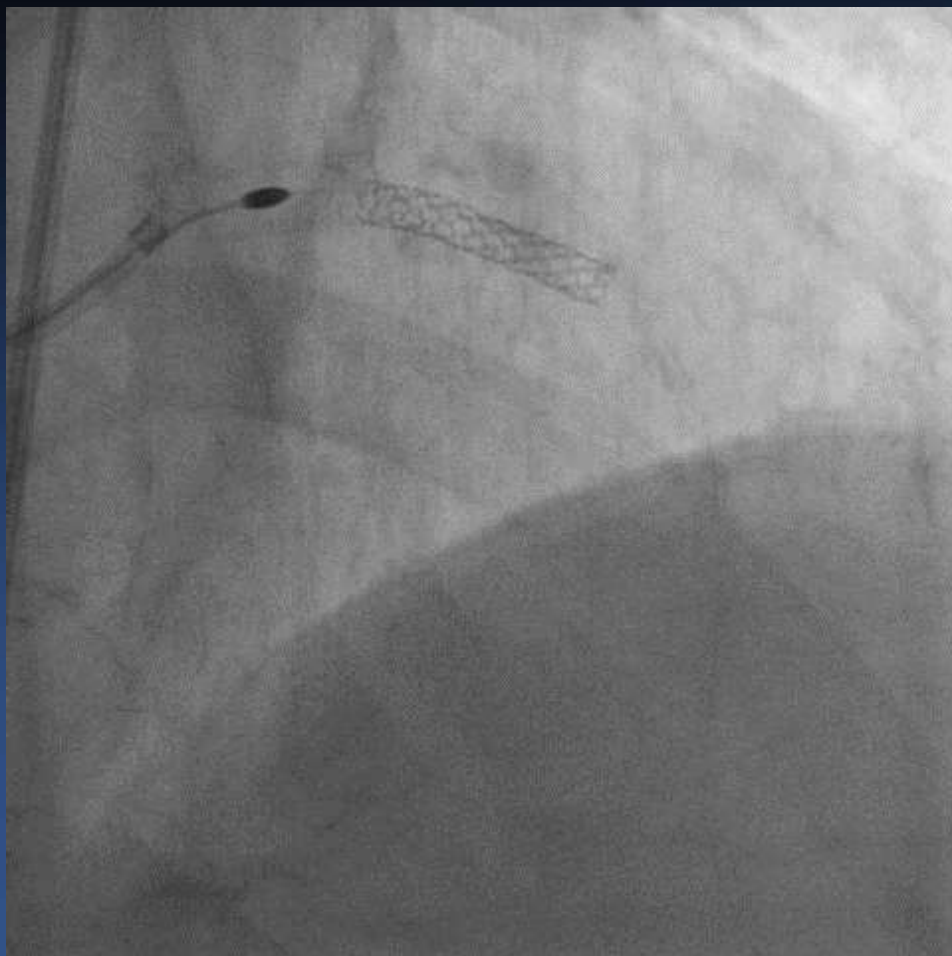
Emerge NC 2.75(20)

Angiosculpt 3.0(15)

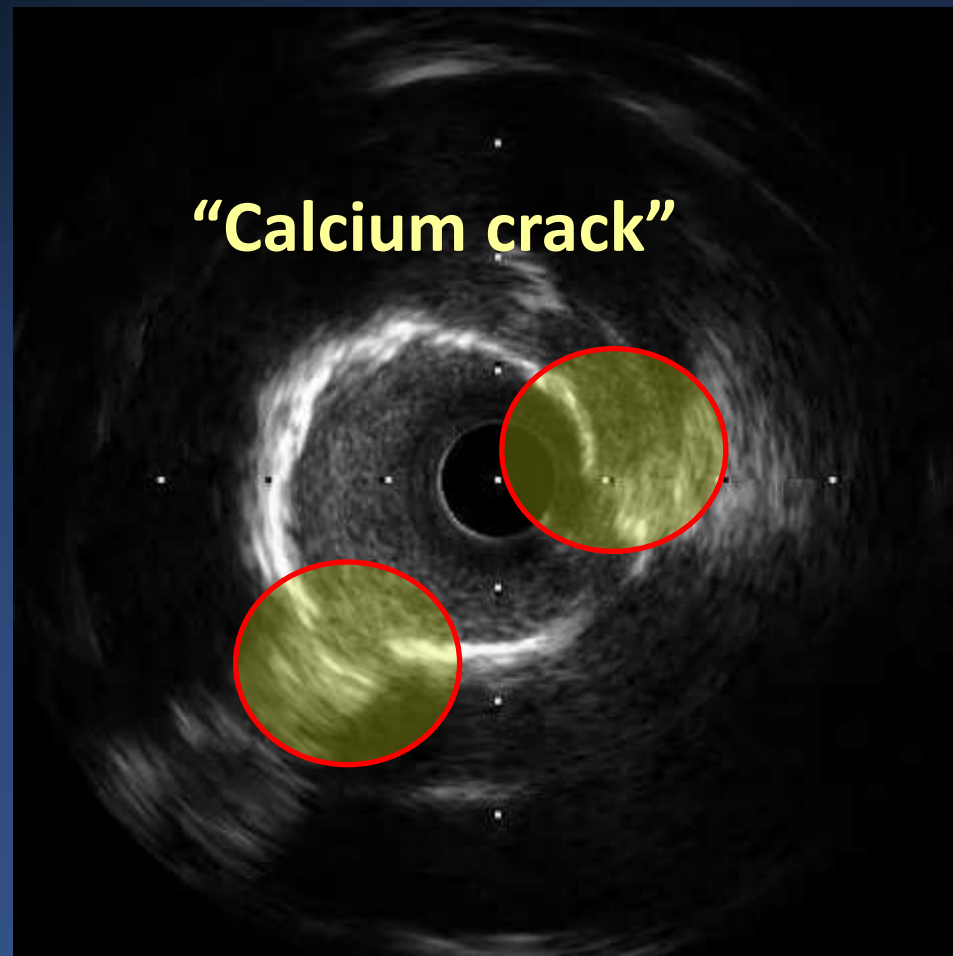


POST IVUS image

Rotablation

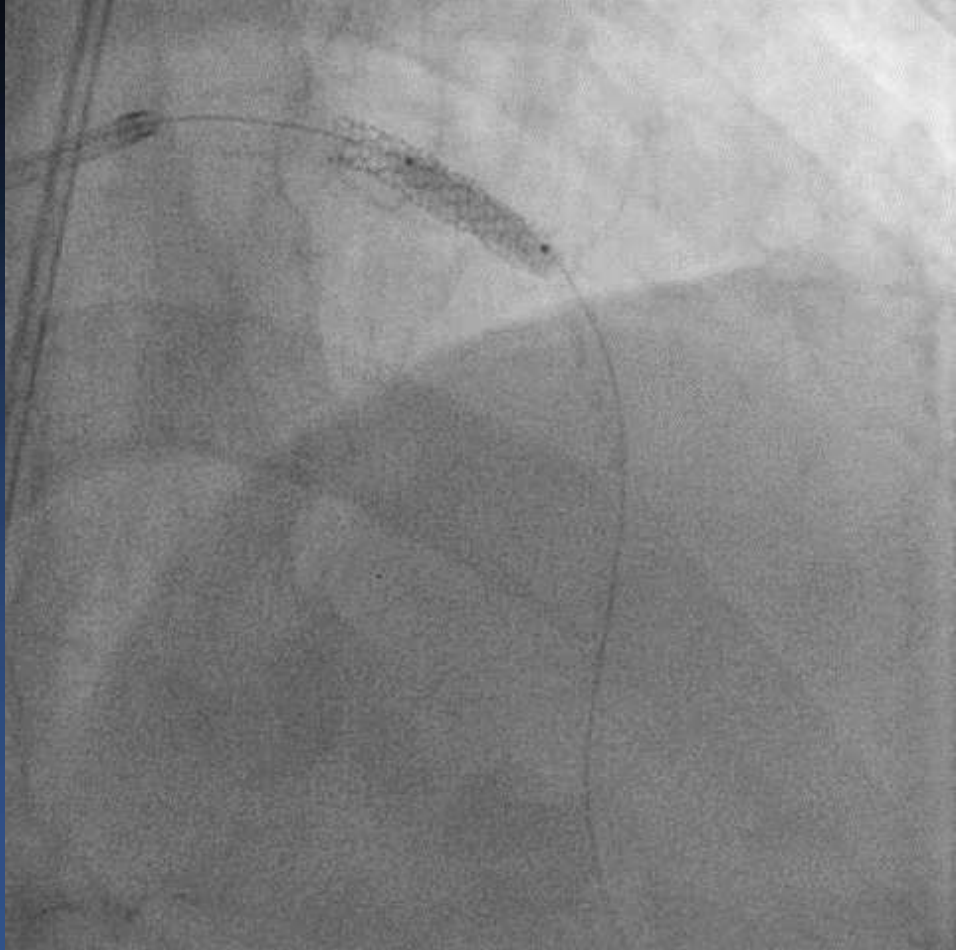


Rotablation 1.5 burr → 1.75 burr



POST IVUS image

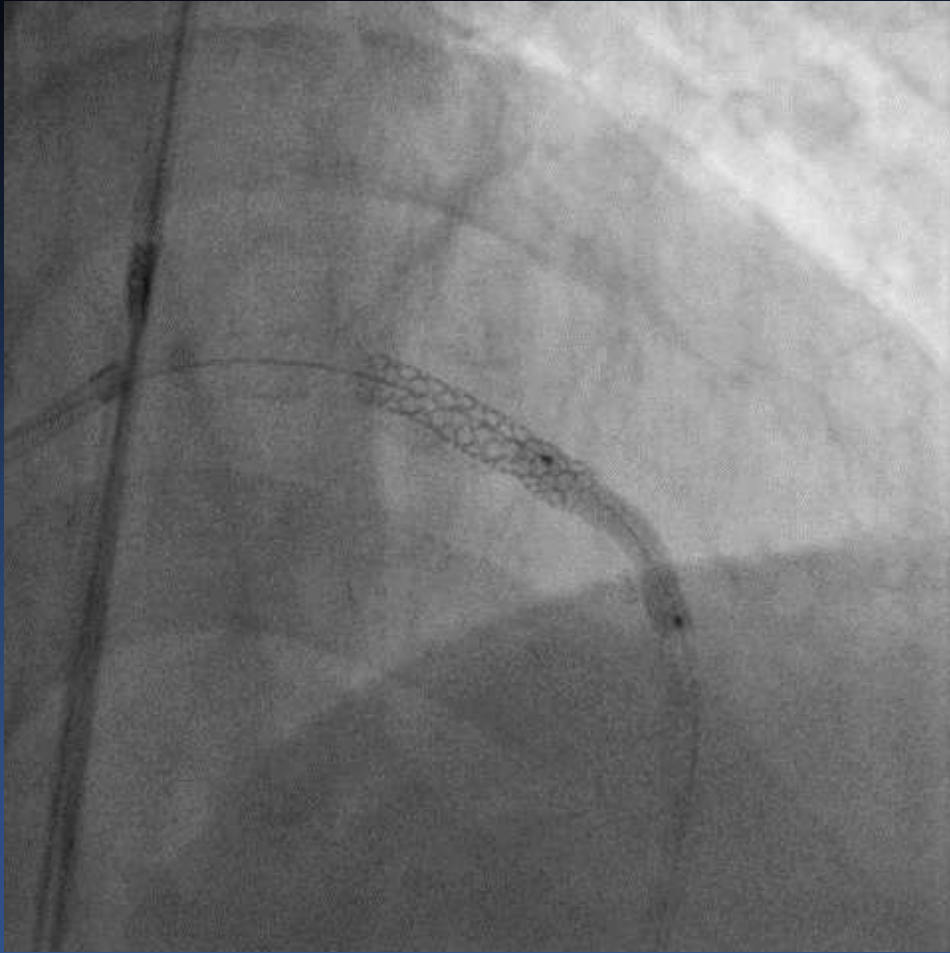
Predilatation



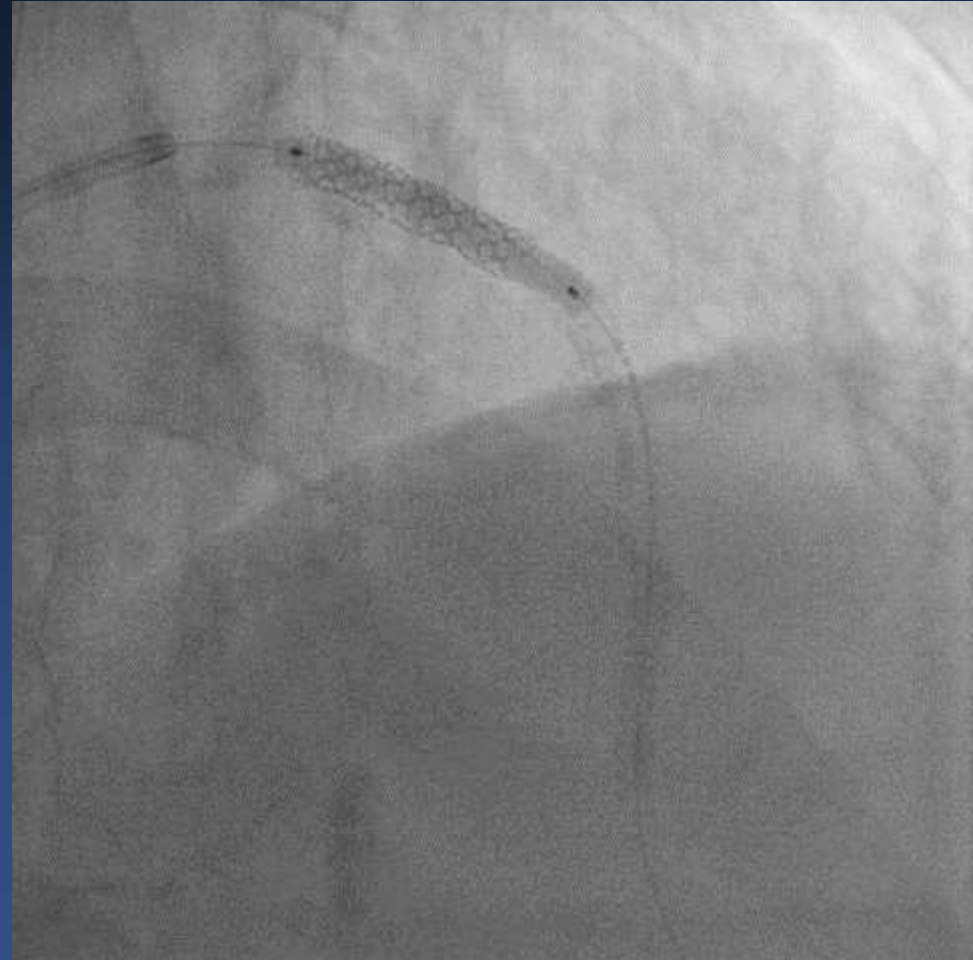
Angiosculpt 3.0(15)

Pantera LEO 3.5(20)

DES and DEB

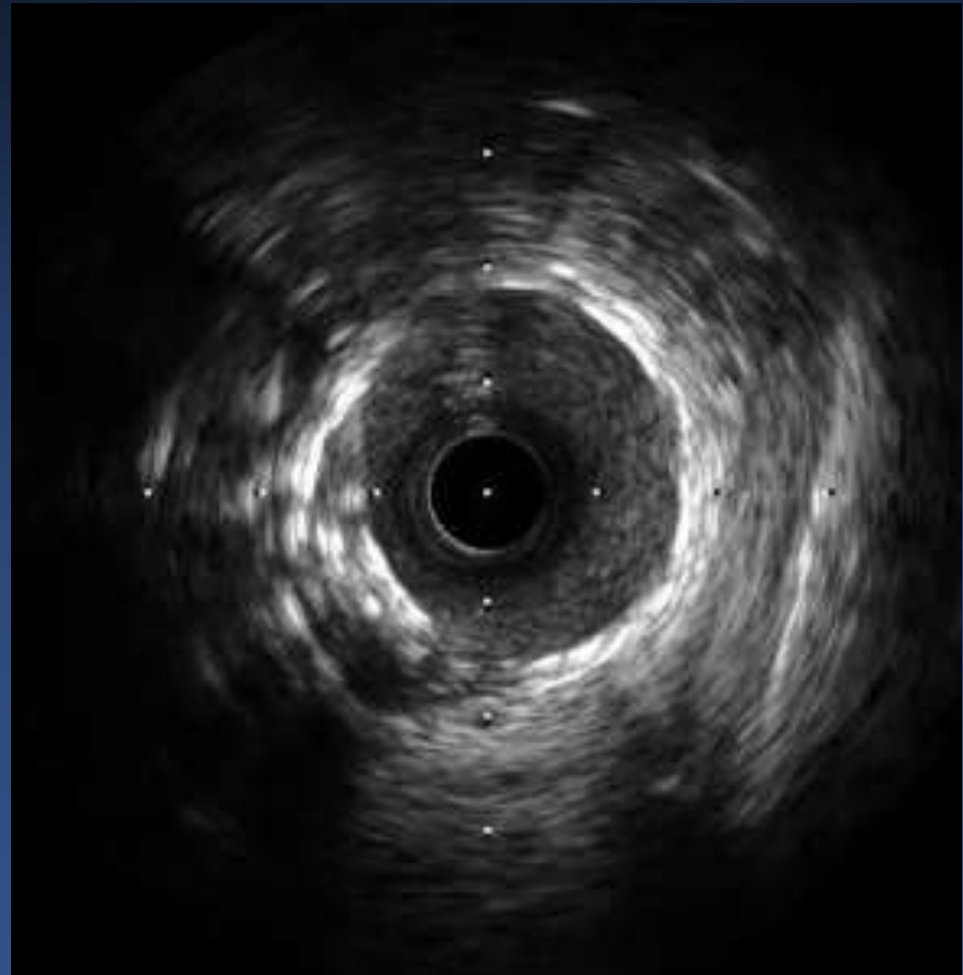
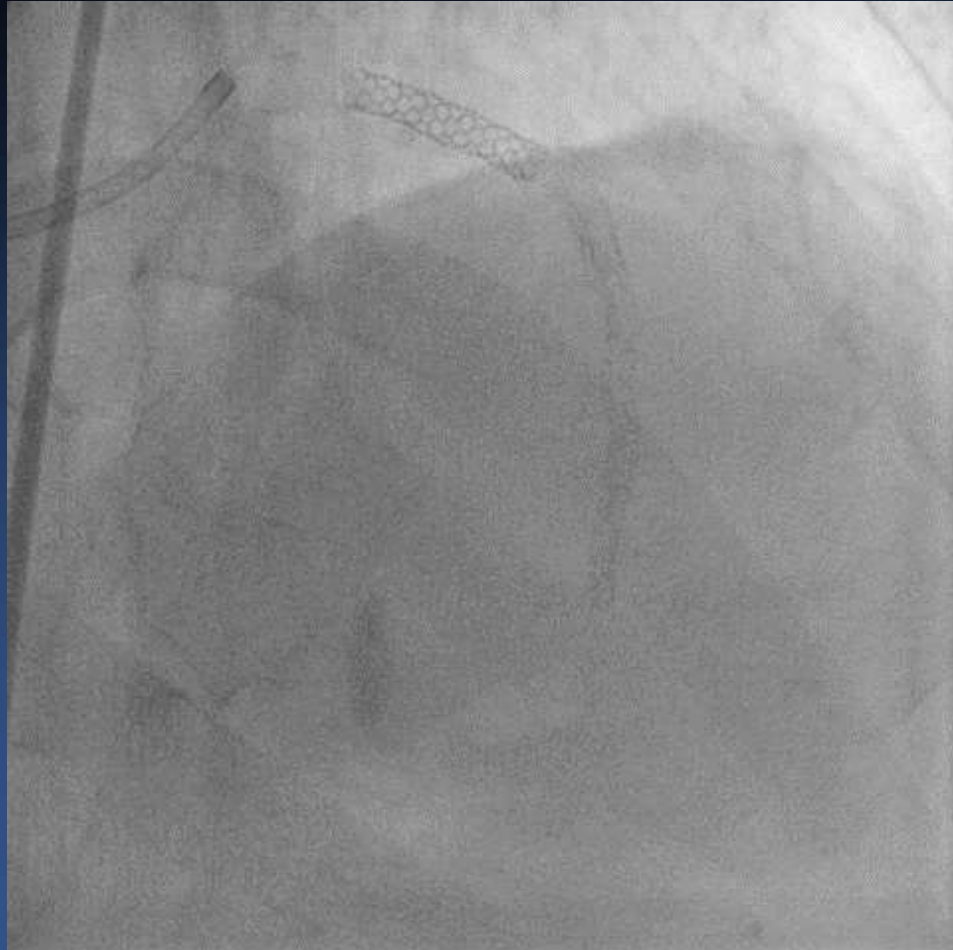


Xience Alpine 2.5(38)
Xience Alpine 3.5(18)



Pantera Lux 3.5(30)

Final image



Tomorrow...

Live Case Demonstrations 2: Calcified Lesion

10:00 AM – 11:30 AM

Main Arena, B2

Moderator(s): [Seong-Wook Park](#), [Teguh Santoso](#), [Seung-Jea Tahk](#)

Panelist(s): [Rosli Mohd Ali](#), [Atsushi Hirohata](#), [Chong-Jin Kim](#), [Seung-Hwan Lee](#), [Abdullah Al Shafi Majumder](#), [Yoshinobu Murasato](#), [Wasan Udayachalerm](#), [Junghan Yoon](#), [Cheuk-Man Yu](#)

- 10:00 AM Asan Medical Center, Seoul, Korea: Case #5
1st Operator: [Jung-Min Ahn](#)
- 10:00 AM Asan Medical Center, Seoul, Korea: Case #6
1st Operator: [Seung-Jung Park](#)
- 10:00 AM Asan Medical Center, Seoul, Korea: Case #7
1st Operator: [Duk-Woo Park](#)
- 10:00 AM Asan Medical Center, Seoul, Korea: Case #8
1st Operator: [Jung-Min Ahn](#)

Thank you for your attention